

## *Latent/Manifest Latent Nystagmus Reversal Using an Ocular Prosthesis Implications For Vision and Ocular Dominance*

L. F. Dell'Osso,\*‡ L. A. Abel,\*‡§ and R. B. Daroff\*‡‡

Latent/manifest latent nystagmus (LMLN) is a jerk nystagmus with a decreasing-velocity or linear slow phase whose fast phase is in the direction of the fixating eye. Change of the fixating eye by alternating tropias or cover will cause reversal of the LMLN to preserve this relationship. In the dark, where no fixation is possible, the fast phases of LMLN are in the direction of the intended fixating eye; actual visual input will override this effect of intention. A patient with persistent hyperplastic primary vitreous of the right eye, which was enucleated at age 9 due to glaucoma, had LMLN with fast phases to the left. His congenitally blind right eye was replaced with an ocular prosthesis whose movements were conjugate with his seeing eye. In the dark, we found that his LMLN *spontaneously* reversed as the normally fixating left eye became esotropic. Furthermore, as is the case with LMLN patients who have sight in both eyes, he was able to willfully reverse his LMLN in the dark by alternating his "fixating" eye. We conclude from these observations that the direction of LMLN is determined at a cortical level, is intimately related to the intended fixating eye and that eye "dominance" is predetermined and not altered by visual abnormalities, including blindness. *Invest Ophthalmol Vis Sci* 28:1873-1876, 1987

Latent nystagmus (LN) was described in 1872<sup>1</sup> as a jerk nystagmus in the direction of a fixating eye when the other eye was occluded or in the direction of gaze when both eyes were open and deviated laterally. Although this first description of LN included its presence with both eyes open, this situation was later regarded as a manifestation of latent nystagmus<sup>2</sup> and led to the term, "manifest latent nystagmus" (MLN).<sup>3</sup> MLN denotes LN present with both eyes open but only one fixating; the other eye is always in a tropic position due to the obligate presence of strabismus.<sup>4</sup> MLN is much more common than pure LN alone; "pure" LN occurs only upon occlusion and not when both eyes are open. Modern methods of ocular motor recording have identified the slow phase waveform as predominantly a decreasing-velocity exponential whose time constant is sometimes large enough to give the appearance of linearity.<sup>3,5</sup>

The term LMLN (latent/manifest latent nystagmus) reflects the current understanding that LN and MLN are mechanistically equivalent and coexist in all but the rare patients who have only LN.<sup>5</sup> No patients have been described who exhibit MLN but not LN. Ishikawa hypothesized that LMLN is sec-

ondary to a proprioceptive rather than a visual disturbance.<sup>6</sup> Dell'Osso et al felt that LMLN is due to the inability to properly calculate egocentric direction under the differing conditions of binocular and monocular fixation.<sup>3</sup> Kommerell and Mehdorn attributed the presence of LMLN to an imbalance in the basic optokinetic reflex.<sup>7</sup> In agreement with the Dell'Osso et al hypothesis, Bedell and Flom recently concluded that a centrally generated nasal drift bias, related to an impairment of spatial directionalization, is responsible for LMLN.<sup>8</sup>

We are reporting a rare patient who had both congenital unilateral blindness and LMLN. For this subject, we use the inclusive term, "LMLN" rather than LN or MLN to avoid semantic difficulties in describing his nystagmus under various conditions. Our study of his nystagmus permitted insight into the mechanism for LMLN and the dual roles of genetic predisposition and visual experience in determining ocular dominance.

**Case History.** A 14 yr old male was referred for evaluation of dizziness on January 14, 1985. He had been blind in his right eye since birth, due to persistent hyperplastic primary vitreous. At age 9, his right eye was enucleated because of painful glaucoma and a prosthesis (Iowa integrated) was inserted. The implant had four posts to which the eye muscles were attached. Recurrent middle ear problems began at age 5. Tubes were repeatedly inserted into the middle ear because of "gait unsteadiness," which improved after each such procedure. At age 12, he developed bilateral intermittent tinnitus and a diagnosis of bilateral Meniere's disease was made. Endolymphatic shunts were placed in the left and right ears in 1983 and 1984, respectively. Movement-induced dizziness returned in August, 1984, prompting chronic use of diazepam.

**Materials and Methods.** Eye movements were recorded using the infrared reflection method (Eye Trac, Model 210) and an 8-channel pen recorder (Beckman Dynograph, Model 612). These were modified so that the total system bandwidth (for both position and velocity channels) was DC to 100 Hz. Normally, calibration of each eye is individually carried out while the other is under cover to provide accurate position information that would reveal any tropias or phorias. In this case, the good eye was calibrated and the tracing for the prosthetic eye was

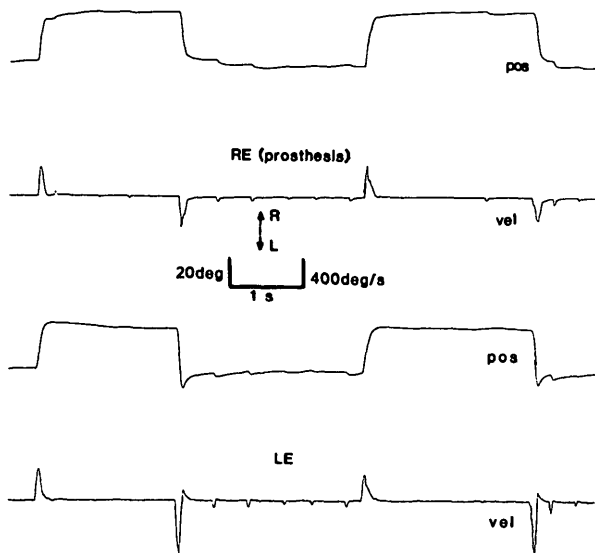


Fig. 1. Position and velocity tracings of both the fixating left eye and prosthetic right eye while viewing targets  $15^\circ$  on the right and left of center. In this and other Figures, R-right, L-left, RE-right eye, LE-left eye, pos-position and vel-velocity.

aligned to it. The gain of the channel for the prosthetic eye was adjusted so that saccadic eye movement analogues were of equal amplitude in both eyes (careful clinical examination revealed the patient's saccades to be conjugate within our ability to discern any differences). Thus, the gain calibration of the position and velocity of the prosthetic eye was accurate

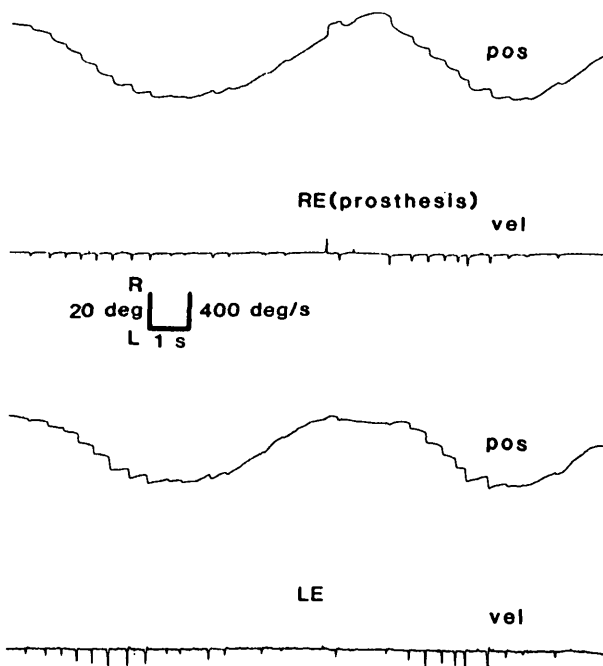


Fig. 2. Position and velocity tracings of both the fixating left eye and prosthetic right eye while tracking a target moving between  $15^\circ$  to the right and left of center.

to within 5–10% by our estimation. Also, this methodology provided us with absolutely valid phase information about both eyes. This allowed comparisons of saccadic trajectory and any changes in ocular alignment that would reflect a tropia or phoria relative to the original alignment. Another paradigm we normally employ with LMLN patients is to instruct them to “look” with each eye individually while both are open. This is done with targets present and in complete darkness. Originally we had not planned to employ that paradigm with this unocular patient. Informed human consent was obtained prior to studying this patient.

**Results.** Clinical testing of the patient's vestibulo-ocular reflex revealed no obvious abnormality; any subtle problems would be obscured by the ongoing LMLN. Consistent with our clinical observations, there was a well-developed, jerk-left LMLN when the patient viewed targets at various gaze angles in a  $\pm 25^\circ$  range (Fig. 1). The nystagmus obeyed Alexander's law. The trajectory of the prosthetic right eye duplicated that of the left eye during the second rightward saccade (Fig. 1). Both eyes show a discrete deceleration during the saccade just after the peak velocity is reached. In Figure 2 the subject is tracking a hand-held target. The jerk-left LMLN superimposed on his tracking creates the impression of a pursuit asymmetry consisting of absent, or low-gain pursuit to the left. As the leftward pursuit signal grew (near primary position) it actually overcame the ever-present rightward slow phase velocity of the jerk-left LMLN, indicating that smooth eye movements to the left were present. During rightward pursuit, the leftward fast phases were suppressed as the subject tracked the target.

When all targets were extinguished and the room totally darkened, a spontaneous change occurred from the previously present jerk-left LMLN to a jerk-right LMLN (Fig. 3a). When we noted this unexpected change, we instructed the patient to “look with his left eye” whereupon the nystagmus reverted to jerk-left LMLN. When instructed to “look with his right eye” it again became jerk-right LMLN. Figure 3b contains illustrative portions of the eye movement records during these maneuvers. Figure 4 contains segments of the pursuit records during tracking of the subject's finger in the dark without fixation instructions (Fig. 4a) and when instructed to track with his right eye (Fig. 4b). In both segments there is an inversion of the left eye signal in far right gaze to artifactual “folding” of the infrared signal. The right eye tracings show that the pursuit “asymmetry” suggested in Figure 2 has reversed. The jerk-right LMLN superimposed on the subject's tracking now caused better pursuit to the left than to the right.

**Discussion.** Haddad et al reviewed 62 cases of persistent hyperplastic primary vitreous (PHPV) and did not report any with nystagmus.<sup>9</sup> We have been unable to find any report or even anecdotal description of the simultaneous occurrence of PHPV and LMLN in a single case. Our patient had an exceedingly rare combination of blindness in one eye (later enucleated and replaced by a prosthesis) and LMLN that normally beats in the direction of the other (fixating) eye. Although rare, the manifestations were appropriate (ie, the nystagmus fast phases in LMLN are always in the direction of the fixating eye). The surprising aspects of this case were in the dark. Here, the LMLN

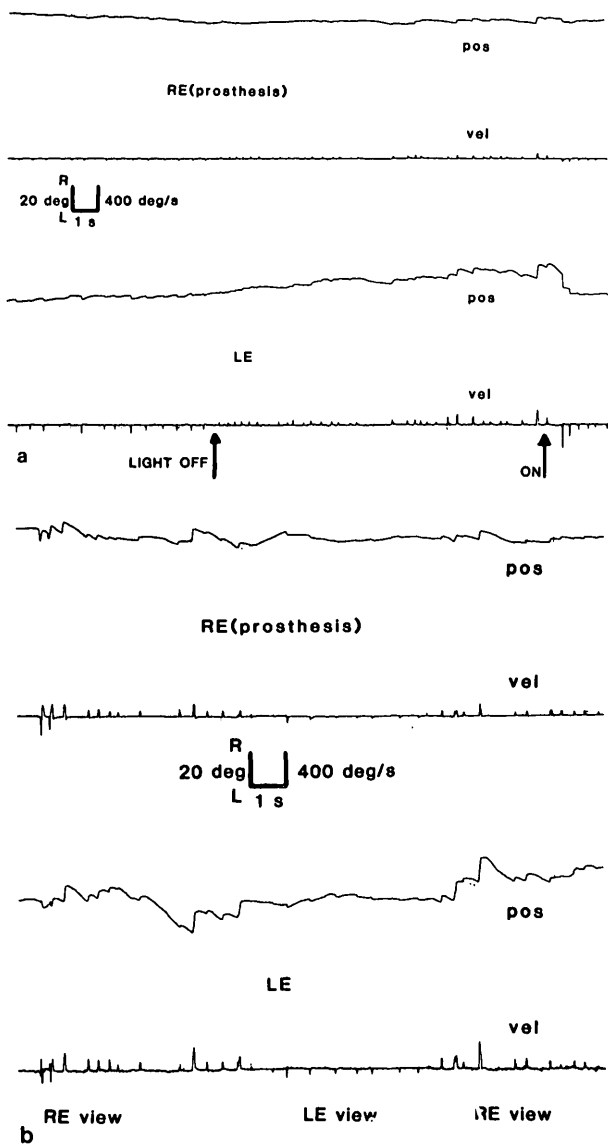


Fig. 3. Spontaneous change from jerk-left LMLN to jerk-right LMLN when the room lights were extinguished and return to jerk left when the lights were turned on (a) the reversal of LMLN in the dark with intent to “view” with either eye (b).

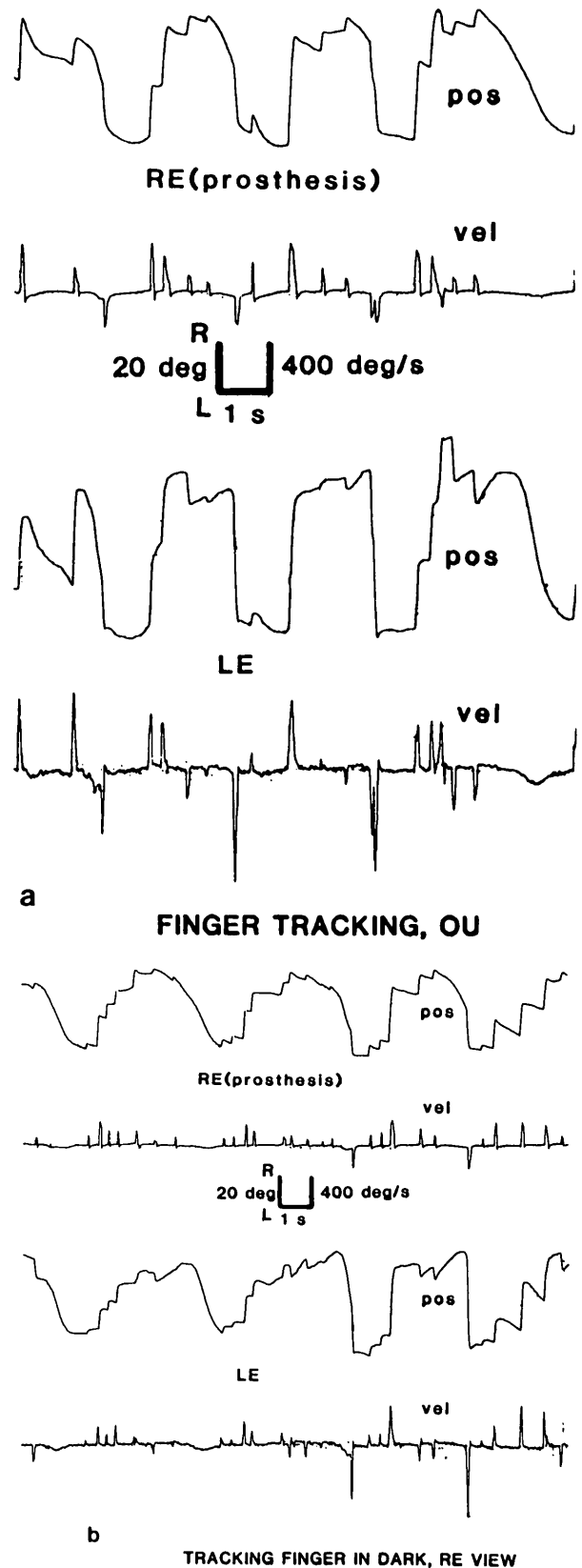


Fig. 4. Position and velocity tracings of both the fixating left eye and prosthetic right eye while tracking finger in the dark with no (a) fixation instructions and (b) when instructed to track with the right eye.

